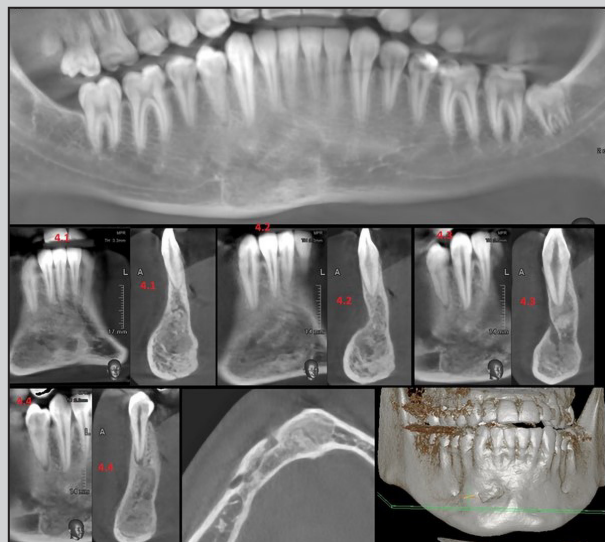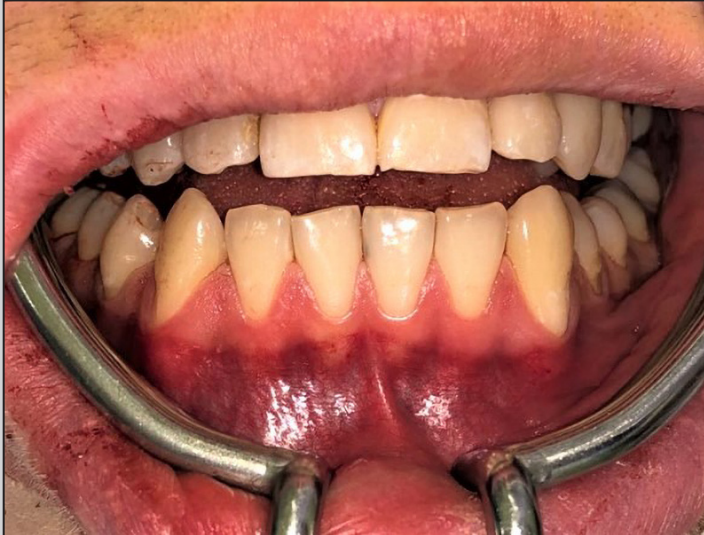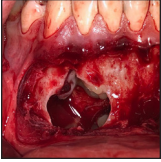


Traumatic Mandibular Cyst Defect Grafted with Autologous Dentin and Platelet-Rich Fibrin Composite: A Case Report



Yan Vares, MD, PhD, DDS¹
Itzhak Binderman, DMD²
Kristina Galyant, MD³

Some cases of asymptomatic traumatic cyst can be sizeable; therefore, they require complete curettage and grafting with bone substitution materials. This case report presents a sizeable traumatic mandibular cyst in a young man treated by surgical exploration and filled with autologous dentin graft (ADG) prepared from extracted an impacted tooth 48 (FDI tooth-numbering system) and advanced platelet-rich fibrin (A-PRF). Initially, an A-PRF membrane was used to cover the apices of teeth 42 and 43, which were protruding into the defect to protect their periapical structures. Then, a grafting strategy was introduced to achieve two fronts of bone formation: one by stimulation of bone outgrowth from the periphery due to A-PRF cellular activity, and a second by bone deposition directly on dentin particles in the center of defect. On CBCT scans performed 7 months postoperatively, arrays of trabeculae that were extending from bone boundaries of the cyst defect were merged with more condensed bone deposited on ADG residuals in the center, thus filling the defect. It was found that autologous dentin combined with cellular A-PRF activity is a powerful tool to restore even sizable bone defects in a relatively short time frame with adequate bone remodeling.

Int J Periodontics Restorative Dent 2022;42:xxx-xxx. doi: 10.11607/prd.5215

It is well known that a traumatic bone cyst is an uncommon lesion that is occasionally diagnosed on routine dental treatment.¹⁻⁴ Morphologically, it is a single lesion surrounded by bony walls without an epithelial lining, either lacking contents or containing liquid and connective tissue. The lesion is mostly diagnosed in patients at a mean age of 20 years, with a slight predominance in men.^{1,2,4} Lesions are mainly situated in the ramus of the mandible, less commonly found in mandibular symphysis, and rarely are in the maxilla.³ Teeth that are located in the projection of the cyst exhibit no mobility or displacement, remain vital, and are absent of root resorption. In most cases, the cyst remains asymptomatic, thus achieving quite a large size and requiring appropriate treatment, which can vary from simple observation to complete curettage and grafting with different kinds of bone substitution materials.¹⁻⁸

Recently, animal and human studies and case reports were published regarding the use of autologous dentin particulate for alveolar ridge preservation, periodontal defects repair, sinus elevations, etc.⁹⁻²² The presence of the Smart Dentin Grinder [Au: Please specify the manufacturer of this product.] technology facilitates using a pa-

¹Department of Maxillofacial Surgery, Lviv National Medical University, Lviv, Ukraine.

²Department of Oral Biology, School of Dental Medicine, and Department of Biomedical Engineering, Faculty of Engineering, Tel Aviv University, Tel Aviv, Israel.

³Private Practice, Lviv, Ukraine.

Correspondence to: Dr Itzhak Binderman, 13, Feivel street, Tel Aviv, 62995, Israel. Email: binderman.itzhak@gmail.com

Submitted June 8, 2020; accepted September 8, 2020.
©2022 by Quintessence Publishing Co Inc.

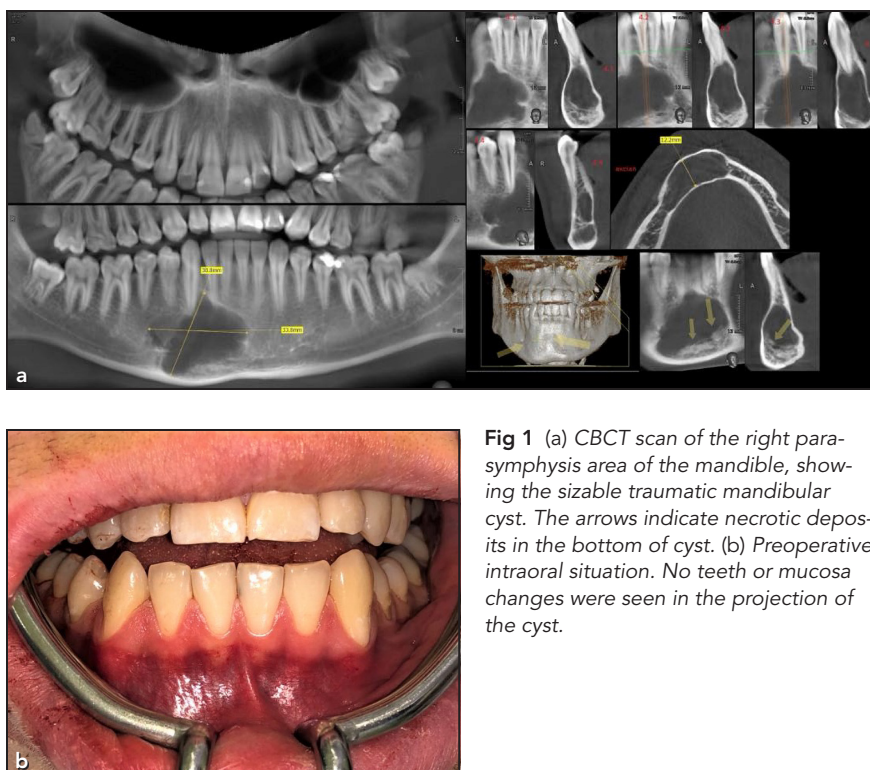


Fig 1 (a) CBCT scan of the right parasymphysis area of the mandible, showing the sizable traumatic mandibular cyst. The arrows indicate necrotic deposits in the bottom of cyst. (b) Preoperative intraoral situation. No teeth or mucosa changes were seen in the projection of the cyst.

tient's own teeth, avoiding the use of both allografts or xenografts.

The present case report details a sizeable traumatic cyst located in the mandible of a young man who was treated by surgical exploration followed by filling of the defect with autologous composition of dentin graft and advanced platelet-rich fibrin (A-PRF) to enhance wound healing and bone regeneration.

Case Presentation and Surgical Treatment

The patient, a 19-year-old man, referred to the Department of Maxillofacial surgery of Lviv National Medical University in August 2019 with complaints regarding the presence of a pathologic formation in the

mandible. Interestingly, the radiolucency on the anterior right mandible was discovered by an orthodontist as part of routine radiographic screening prior to orthodontic treatment that included the removal of impacted third molars (Fig 1a). Patient had no complaints—no deformation of dental arches or sensory disturbances of the inferior alveolar or mental nerves—but reported a trauma to the chin approximately 9 years prior when he fell from a bicycle. Since then, the formation was asymptomatic.

On intraoral clinical examination, a slight deformation of the mandibular body in the right parasymphysis area was found, although the overlying mucosa appeared normal (Fig 1b). The teeth in the projection of the formation were im-

mobile and painless on percussion. Electric pulp testing with a Digitest device (Parkell) revealed decreased excitability of teeth 42 and 43 (FDI tooth-numbering system) in comparison with the neighboring teeth. Bloody exudate was aspirated from the lesion. CBCT scans (Fig 1a) revealed a $34 \times 31 \times 12$ -mm unilocular, lobulated, radiolucent area (12.65 cm^3) with a sclerotic border extending from the inferior aspect of the mandibular right incisor and canine apices to the mandibular inferior border, and from the mandibular midline to the loop of the right mental nerve. Lobulated extensions were well defined between the lateral incisor and canine on the right, but the lamina dura of these teeth were intact. There was significant expansion of the vestibular cortical plate without perforation.

Based on clinical and radiologic examinations, the patient was given a diagnosis of traumatic mandibular cyst in the right parasymphysis area. The patient was informed about the nature of the intervention, possible risks associated with the removal, and the need to replace the residual defect with materials of autologous, allogeneic, xenogenic, or synthetic origin. Because the impacted tooth (no. 48) was planned to be extracted in the orthodontic treatment plan, it was proposed to simultaneously remove the cyst and use tooth 48 as an autologous particulate graft.

In accordance with the bioethics regulations of the Lviv National Medical University Institutional Review Board, the patient signed an informed consent form for the treatment, which included local an-

esthesia with premedication, surgical removal of the cyst, blood sampling for preparation of A-PRF, open (surgical) removal of the mesially impacted tooth 48 for preparation of autologous dentin graft (ADG), and substitution of the defect with autologous composition. Four days after the initial clinical evaluation, cyst exploration, eradication, and the replacement of the defect by an autologous composition of dentin and A-PRF was made under regional conduction anesthesia (6.0 mL of Sol. Ubisthesini 4% [Au: Does "Sol" mean "solution"?]) with premedication (2.0 mL of Sol. Analgini 50%; 1.0 mL of Sol. Dimedroli 1% [Au: Please specify the manufacturer(s) of the products Ubisthesini, Analgini, and Dimedroli.]). Initially, a vestibular submarginal incision was performed within the limits of teeth 33 to 44 [Au: 43?], and a mucoperiosteal flap was reflected. With the help of a spherical surgical bur, a thinned cortical plate in the projection of the cyst was trepanned, and a bone window was made. Through the access created, a thorough mechanical curettage of the defect was performed with removal of connective tissue fragments and blood exudate, and the defect cavity was irrigated with antiseptic solution (Sol. chlorhexidine 0.05% and Sol. hydrogen peroxide 3%). A histologic examination revealed blood elements with connective tissue and no epithelium, which confirmed the diagnosis of a traumatic cyst.

Before starting the next surgical step, 100 mL of venous blood was drawn from the patient and put into 10 test tubes that were immediately

placed in a Duo Quattro centrifuge (Process for PRF) and prepared according to the low-speed centrifugation concept (1,300 rpm for 8 minutes).^{23,24} Afterward, the caps of the tubes were removed, and the fibrin clots were gently separated by peeling them from red blood cells. Six of the resulting clots were pressed in the PRF box to form membranes.

Later, under regional conduction anesthesia (4.0 mL of Sol. Ubisthesini 4%), an angular incision was made in projection of tooth 48, the mucoperiosteal flap was elevated, and the bone tissue around the crown of the impacted tooth was removed using a surgical bur and an elevator. After socket curettage, it was filled with a collagen block [Au: Please list the product name and manufacturer of the collagen block.] and sewed with 4.0 nonresorbable material (Seralon, Serag Wiessner).

A dentin particulate autograft was prepared according to the manufacturer's recommendations and a previously described protocol.^{10,12,18,20} In brief, the extracted tooth was thoroughly and mechanically cleaned using a high-speed carbide bur. PDL [Au: The periodontal ligament?] on the outer layer of the enamel was removed before pulverizing the tooth. The clean tooth was dried by an air syringe and placed in a sterile chamber of a dentin grinding device (Smart Dentin Grinder, KometaBio) to produce particles sizes of 300 to 1,200 μm , which were sieved into the collection tray after grinding. The obtained graft was immersed in a basic alcohol cleanser in a sterile

container for 5 minutes to dissolve all organic remnants and bacteria, then dehydrated with sterile gauze. The particles were then rinsed twice with a sterile phosphate-buffered saline solution and again dehydrated with sterile gauze. Later, scissors were used to chop some of the fibrin clots, and they were placed in a metal cup and mixed thoroughly with the particulate dentin to form a homogenous matrix. [Au: Sentence correct as edited?]

Grafting Procedure

A specific process was used for defect repair. First, an A-PRF membrane was used to cover the apices of teeth 42 and 43, which were projected into the defect (Fig 2a). This was done to avoid potential focused inflammation and pulp necrosis and to allow regeneration of the architecture and function of the original periapical tissues.²⁵ Then, the distal (peripheral) aspects of the bone cavity were filled with A-PRF clots while the mixture of ADG with A-PRF was placed in the central part of the defect (Fig 2b). Finally, the graft was covered with A-PRF membranes, and the wound was closed with 4.0 nonresorbable sutures (Seralon). It should be noted that PRF consists of leukocytes, including macrophages, that are embedded in fibrin filaments and cross-linked to fibronectin, providing a provisional matrix for attachment and migration of immune cells, endothelial cells, and tissue cells that are instrumental in regenerative procedures.

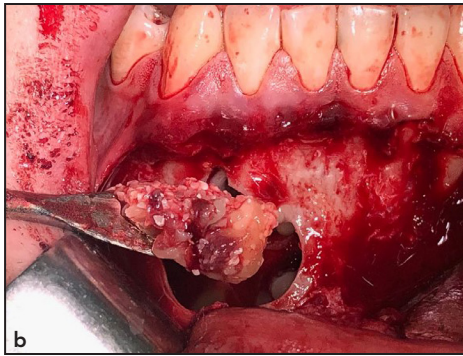
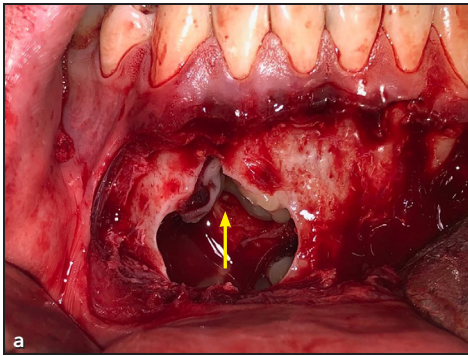


Fig 2 (a) Covering the root apices (yellow arrow) and peripheral boundaries of residual bone with A-PRF membranes. (b) Placing autologous dentin particulate mixed with A-PRF clot in the central part of the defect, supported buccally with A-PRF membrane (not shown).

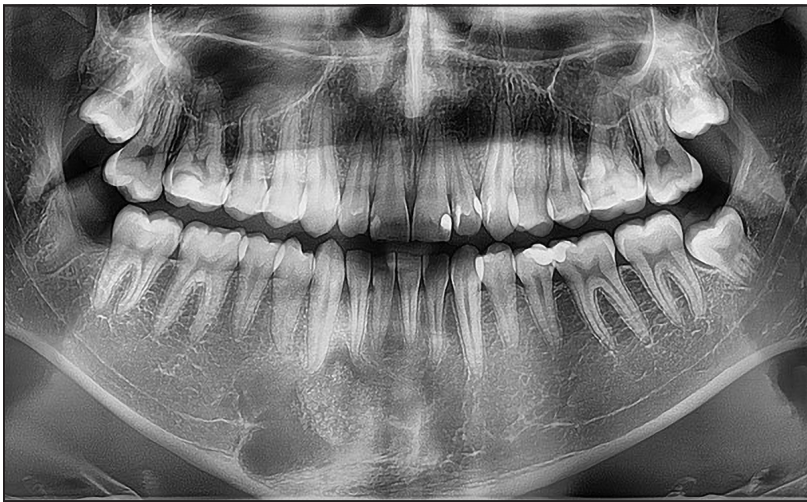

Fig 3 Panoramic radiographic view at 2 months postoperative. Partial bone repair and nonresorbed, dense ADG are still visible.

In the postoperative period, the patient was prescribed oral antibiotic therapy (Augmentin, GlaxoSmith-Kline; 1 g/day for 6 days), a nonsteroid analgesic (Brufen, Abbott; 600 mg on request), and chlorhexidine mouthwash. The sutures were removed after 10 days. The patient was followed up weekly for the first month, then monthly until evidence of complete healing was observed.

Follow-up

On panoramic radiographs taken 2 months postoperative, dentin graft

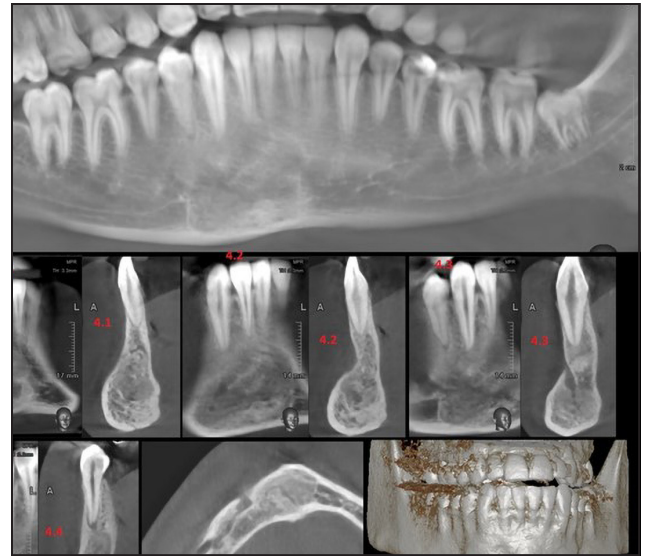particles were visible in the central part of the defect, and there were no radiographic signs of active bone regeneration in its peripheral areas (Fig 3). Five months postoperatively, a homogenous primary osseous structure filled most of the defect, resembling the structure of neighboring normal bone (not shown). Interestingly, teeth 42 and 43, which preoperatively demonstrated lower sensitivity during electric pulp testing, regained their excitability to the normal rate within 5 months post-surgery.

On CBCT scans performed 7 months postoperatively (Fig 4), ar-

rays of trabeculi extending from the bone boundaries of the cyst defect were seen to have merged with more condensed bone in the center. No areas with pathologic radiographic patterns were observed. The normalization of the mandibular vestibular cortical plate shape (absence of expansion) was observed in axial projection.

Numerical evaluation of bone density was performed using a profile grayscale evaluation system (Ez3D 2009, E-Woo Technology [Au: Manufacturer correct?]) on CBCT radiographs in an untreated mandibular site (between teeth 33

Fig 4 CBCT scans taken 7 months postoperative. Complete regeneration of the cyst defect by dense bone can be seen. Additionally, the vestibular cortical plate shape reverted to its original shape and thickness (in comparison to contralateral side).



and 34), revealing 300 units, while bone density of the grafted area (between teeth 43 and 44; Fig 5), where a regenerative structure of reparative bone was formed by a combined mixture of ADG and A-PRF, revealed a density 3X greater than seen at the untreated site. The high bone density of the grafted mandibular site was possibly due to the newly formed bone ankylosed to mineralized dentin particulate.

Discussion

Although the traumatic mandibular cyst is well described in medical literature, some aspects of its treatment protocols remain controversial. In cases of small cysts, observation is possible. However, the “watch and wait” approach has led to diagnostic errors and might allow for more aggressive lesions to keep growing, which in turn allows for additional complications such as pathologic fracture, involvement of adjacent

teeth, and the need for bigger surgical intervention.⁴ For this reason, some authors insist on a patient’s availability for a long follow-up period when a nonsurgical protocol is chosen.²⁶ To treat a traumatic cyst in the dental arch, Brunet-Llobet et al⁷ proposed an advanced treatment protocol; in their patient (a 15-year-old child), continuous surgical decompression was performed for a long time [Au: Sentence correct as edited?]. In another study, Aiba et al⁵ suggested endoscopic curettage as a minimally invasive method for treating aneurysmal bone cysts.

The gold standard treatment modality in the management of traumatic bone cyst is enucleating the cyst, followed by curettage of the cystic cavity and inducing fresh bleeding into the surgical site, with an expected healing period of 6 to 24 months.^{1,3,4,27} Çelik et al²⁸ suggested that inadequate curettage of the cyst can lead to recurrence as a result of residual proliferating tissues. Moreover, precise curettage is

necessary for inducing fresh bleeding and wound healing, which in turn may promote osteogenesis to fill the bone cavity.^{1,4} Subramaniam et al⁸ claimed that careful curettage and the use of plasma-rich protein as a means of bone regeneration led to faster and more favorable healing. Other treatment approaches, such as application of bone allografts and insertion of a gelfoam saturated with penicillin and thrombin, have also employed.⁶

To best of the present authors’ knowledge, this is the first case report that describes the use of ADG and PRF in the treatment protocol of a traumatic mandibular cyst. It appears that the collective role of precise bone curettage for induction of peripheral bleeding, PRF (which contains cellular and matrix regenerative components), and ADG (with its excellent osteoinductive and osteoconductive properties) has the ability to completely heal huge mandibular cyst defects in a relatively short time period. Moreover, there

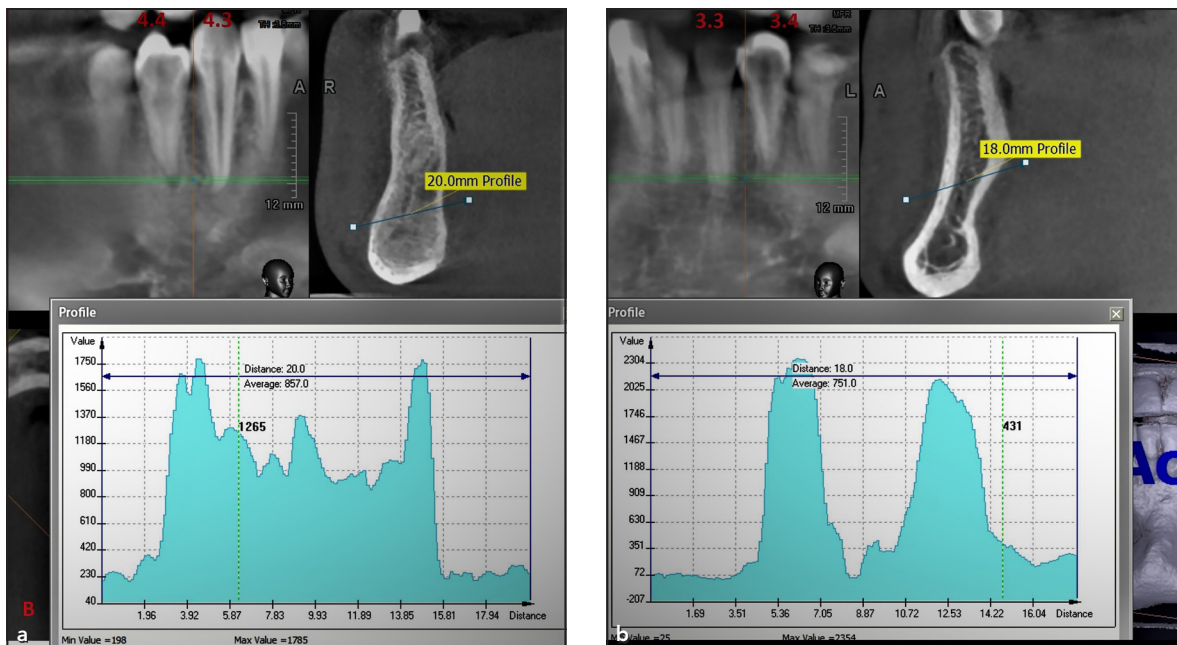


Fig 5 Comparison of bone density surrounding (a) the untreated normal side (teeth 33 and 34) and (b) the grafted site surrounding teeth 43 and 44. [Au: At what time point were these radiographs/CBCT scans taken? 7 months postoperatively? Please clarify.]

is typically an imminent availability of autologous dentin, considering that traumatic jaw cysts mainly occur in young adults, where many of the patients have compromised third molars.¹⁷ The idea to combine two surgeries—exploration of the cyst and tooth removal—in order to retrieve ADG for the defect restoration appears satisfactory and efficient.

The strategy of first grafting A-PRF at the periphery of bone boundaries, and especially around the roots, provided a regenerative layer of leukocyte concentrate, including monocyte-macrophage populations embedded in the fibrin-fibronectin network of the forming matrix. It is based on advanced biologic wound healing concepts. Monocytes and macrophages play a critical role in tissue development, homeostasis, and injury repair, and

they span a continuum of inflammatory (M1) and anti-inflammatory or pro-regenerative cells (M2); their heterogeneous functions are highly dependent on microenvironmental cues within the injury niche.²⁹ Moreover, macrophages have the ability to sense and interact with the biomaterial surface's physical and chemical properties, signaling the stimulation of angiogenesis and activity of local stem and progenitor cells. Once stimulated, these progenitor cells can initiate the structural repair of tissues, such as muscle and bone.²⁹ The interaction between A-PRF with ADG initially induces new bone formation that becomes ankylosed to dentin particles, followed by a slow remodeling of dentin that is replaced by newly formed bone. It is therefore reasonable to suggest that two vectors of bone formation merge: Bone for-

mation extends from the peripheral boundaries of the defect, growing toward the center and merging with the bone that is deposited directly on the dentin particles in the center of the defect, which are growing outwards [Au: Sentence correct as edited?]. This may explain the fast regeneration of the cyst cavity in the young patient in the present case report. Therefore, the selection of a scaffold biomaterial and its grafting procedure are critical for achieving optimal regeneration of a high-density alveolar ridge bone structure. The autologous dentin particulate, like autologous cortical bone grafts, naturally attracts patient's blood cells and osteogenic precursors, which deposit mineralized bone matrix directly upon dentin surfaces and create connectivity between dentin and the host bone.²⁰

Conclusions

The present clinical case report demonstrates that extracted tooth particles in combination with PRF can be used to successfully repair dental arch defects after enucleation/exploration of cysts of different origin, particularly traumatic types.

Acknowledgments

[Au: Please provide a conflict of interest statement.]

References

- Kumar LK, Kurien N, Thaha KA. Traumatic bone cyst of mandible. *J Maxillofac Oral Surg* 2015;14:466–469.
- Razmara F, Ghoncheh Z, Shabankare G. Traumatic bone cyst of mandible: A case series. *J Med Case Reports* 2019;13:300.
- Resnick CM, Dentino KM, Garza R, Padwa BL. A management strategy for idiopathic bone cavities of the jaws. *J Oral Maxillofac Surg* 2016;74:1153–1158.
- Titsinides S, Kalyvas D. Traumatic bone cyst of the jaw: a case report and review of previous studies. *J Dent Health Oral Disord Ther* 2016;5:318–325.
- Aiba H, Kobayashi M, Waguri-Nagaya Y, et al. Treatment of aneurysmal bone cysts using endoscopic curettage. *BMC Musculoskelet Disord* 2018;19:268.
- Huebner GR, Turlington EG. So-called traumatic (hemorrhagic) bone cysts of the jaws: Review of the literature and report of two unusual cases. *Oral Surg Oral Med Oral Pathol* 1971;31:354–365.
- Brunet-Llobet L, Lahor-Soler E, Mashala El, Miranda-Rius J. Continuous surgical decompression for solitary bone cyst of the jaw in a teenage patient. *Case Rep Dent* 2019;6:9137507.
- Subramaniam P, Kumar K, Ramakrishna T, Bhadranna A. Bone regeneration with plasma-rich-protein following enucleation of traumatic bone cyst. *Eur J Dent* 2013;7:377–381.
- Andrade C, Camino J, Nally M, Quirynen M, Martínez B, Pinto N. Combining autologous particulate dentin, L-PRF, and fibrinogen to create a matrix for predictable ridge preservation: A pilot clinical study. *Clin Oral Investig* 2020;24:1151–1160.
- Binderman I, Hallel G, Nardy C, Yaffe A, Sapoznikov L. A novel procedure to process extracted teeth for immediate grafting of autogenous dentin. *J Interdiscipl Med Dent Sci* 2014;2:154.
- del Canto-Díaz A, de Elío-Oliveros J, del Canto-Díaz M, Alobera-Gracia MA, del Canto-Pingarrón M, Martínez-González JM. Use of autologous tooth-derived graft material in the post-extraction dental socket. Pilot study. *Med Oral Patol Oral Cir Bucal* 2019;24:53–60.
- Cardaropoli D, Nevins M, Schupbach P. New bone formation using an extracted tooth as a biomaterial: A case report with histologic evidence. *Intern J Periodontics Restorative Dent* 2019;39:157–163.
- Demiragi G, Noçka E, Sulaj E, Corigliano M, Budina R. Tooth graft socket augmentation and immediate implant placement: Case report. *Revista Stomatologjike Shqiptare* 2019;60:14–20. [Au: Correct? This article could not be found when verifying references. Please confirm it is correct and provide a link, if possible.]
- Jun SH, Ahn JS, Lee JI, Ahn KJ, Yun PY, Kim YK. A prospective study on the effectiveness of newly developed autogenous tooth bone graft material for sinus bone graft procedure. *J Adv Prosthodont* 2014;6:528–538.
- Kim YK, Kim SG, Byeon JH, et al. Development of a novel bone grafting material using autogenous teeth. *Oral Surg Oral Med Oral Pathol Oral Radiol Endod* 2010;109:496–503.
- Khanijou M, Seriwatanachai D, Boonsiriseth K, et al. Bone graft material derived from extracted tooth: A review literature. *J Oral Maxillofac Surg Med Pathol* 2019;31:1–7.
- Kuperschlag A, Keršytė G, Kurtzman GM, Horowitz RA. Autogenous dentin grafting of osseous defects distal to mandibular second molars after extraction of impacted third molars. *Compend Contin Educ Dent* 2020;41:76–82; quiz 83.
- Mazor Z, Horowitz RA, Prasad H, Kotsakis GA. Healing dynamics following alveolar ridge preservation with autologous tooth structure. *Int J Periodontics Restorative Dent* 2019;39:697–702.
- Nampo T, Watahiki J, Enomoto A, et al. A new method for alveolar bone repair using extracted teeth for the graft material. *J Periodontol* 2010;81:1264–1272.
- Pohl S, Binderman I, Tomac J. Maintenance of alveolar ridge dimensions utilizing an extracted tooth dentin particulate autograft and platelet-rich fibrin: A retrospective radiographic cone-beam computed tomography study. *Materials (Basel)* 2020;13:1083.
- Schwarz F, Golubovic V, Becker K, Mihatovic I. Extracted tooth roots used for lateral alveolar ridge augmentation: A proof-of-concept study. *J Clin Periodontol* 2016;43:345–353.
- Schwarz F, Hazar D, Becker K, Sader R, Becker J. Efficacy of autogenous tooth roots for lateral alveolar ridge augmentation and staged implant placement. A prospective controlled clinical study. *J Clin Periodontol* 2018;45:996–1004.
- Choukroun J, Ghanaati S. Reduction of relative centrifugation force within injectable platelet-rich-fibrin (PRF) concentrates advances patients' own inflammatory cells, platelets and growth factors: The first introduction to the low speed centrifugation concept. *Eur J Trauma Emerg Surg* 2018;44:87–95.
- Fujioka-Kobayashi M, Miron RJ, Hernandez M, Kandalam U, Zhang Y, Choukroun J. Optimized platelet-rich fibrin with the low-speed concept: growth factor release, biocompatibility, and cellular response. *J Periodontol* 2017;88:112–121.
- Newton CW, Zunt SL. Endodontic intervention in the traumatic bone cyst. *J Endod* 1987;13:405–408.
- Battisti MPL, Soares MQS, Rubira CMF, Bullen IRFR, Lauris JRP, Damante JH. Assessment of spontaneous resolution of idiopathic bone cavity. *J Appl Oral Sci* 2018;26:e20170288.
- Madan R, Sharma S, Balani A, Rathod P, Hathgain U, Sharma M. Traumatic bone cyst of the mandible: A case report and brief review of the literature. *Int J Oral Care Res* 2018;6:117–120.
- Çelik S, Uludağ A, Tosun HB, Serbest S, Gürger M, Kılıç S. Unicameral (simple) and aneurysmal bone cysts: The effect of insufficient curettage on recurrence. *Pan Afr Med J* 2016;24:311.
- Ogle ME, Segar CE, Sridhar S, Botchwey EA. Monocytes and macrophages in tissue repair: Implications for immunoregenerative biomaterial design. *Exp Biol Med (Maywood)* 2016;241:1084–1097.